

Cough and Fever in cancer patient, which is the diagnosis?

Tos y fiebre en paciente oncológica, ¿cuál es su diagnóstico?

Gatica, David^{1,2}; Pitrella, Alicia³; Villalobos, Walter⁴

CASE REPORT

We received a clinical medicine cross-consultation of a 56-year-old female patient with history of appendiceal mixed adenoneuroendocrine carcinoma, diagnosed on September 3rd, 2019: pT4a pN2 pMx, who received chemotherapy as first line of treatment. Subsequent follow-up was done through PET/CT (positron emission tomography/computed tomography), and the results indicated disease progression without lung compromise. In February 2021, the patient began treatment with immunotherapy (nivolumab/ipilimumab) until September 2021, when it was decided that the treatment had to be suspended because the patient started to have nonproductive cough, fever of 38 °C predominantly at night for one month, chest pain and dyspnea, functional class 4 according to the mMRC (Modified Medical Research Council) scale. She was hospitalized at the internal medicine department with regular general condition, alert, blood pressure: 80/50 mmHg. Expansion with physiological solution with good response, blood pressure: 100/60 mmHg, heart rate: 82 beats/min, breathing rate: 19 bpm, oxygen saturation: 95% (FiO₂: 0.21). Semiology of the respiratory system: normal breath sounds. Laboratory testing on admission: hematocrit 29%, hemoglobin: 9.8 mg/dL, leucocytes: 13,330 mm³, segmented neutrophils: 10,260 mm³, band neutrophils 27 mm³, lymphocytes: 1690 mm³, uremia: 41.1mg/dL, creatinine: 0.99 mg/dL, normal hepatogram. Arterial blood gases: pH: 7.45, pCO₂: 36.2 mmHg, pO₂: 82.6 mmHg, SatO₂: 96.7%, bicarbonate: 24.7 mmol/L, lactate: 1.25 mmol/L.

Chest CT (11/10/2021) (See Figure 1):

The CT shows multiple peribronchovascular “ground glass” infiltrates with central and peripheral distribution, with compromised patchy lungs predominantly bibasilar, and consolidations with air bronchogram in left posterior basal segment.

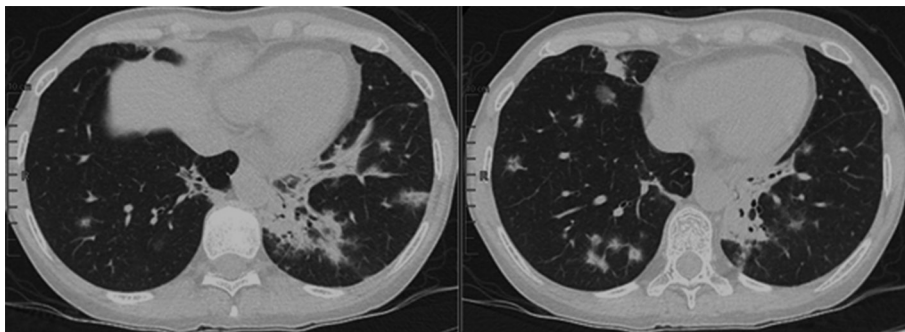


Figure 1. Chest tomography 11/10/2021.

Rev Am Med Resp 2022;22:235-238
<https://doi.org/10.56538/ramr.TXVT8924>

Correspondence: E-mail: drdavidgatica@gmail.com

¹ Hospital Del Carmen, Department of Pneumology.

² Universidad Nacional de Cuyo, Faculty of Medical Sciences, Mendoza, Argentina.

³ Hospital Del Carmen, Department of Diagnostic Imaging, Mendoza, Argentina.

⁴ Fundación Escuela de Medicina Nuclear FUESMEN.

Which are the diagnoses?

- 1 Pneumonia: viral, bacterial, mycosis.
- 2 Progression of oncological disease to the lungs.
- 3 Checkpoint inhibitor-associated pneumonia.

During hospitalization, the patient underwent a fibrobronchoscopy with bronchoalveolar lavage. The bacteriology report and viral panel were negative, so the empiric antibiotic therapy was suspended due to suspected pneumonia (it started after the fibronchoscopy) and the patient began treatment with 1 mg/kg/d of corticosteroids. The mycology report, acid-fast bacillus culture and biopsy sent to the department of pathological anatomy are still pending. The patient was discharged due to improved clinical symptoms, with presumptive diagnosis of checkpoint inhibitor-associated pneumonia.

DIAGNOSIS

Corticoids were suspended gradually (2 months of treatment). The patient consulted again for dry cough and fever of more than 38 °C, which was partially lowered with paracetamol, 1 g. She brought a pathological anatomy report of a transbronchial biopsy: associated with organizing pneumonia.

New CT requested **01/21/2022** (Figure 2): reduced bibasilar infiltrates with appearance of new infiltrates in upper lobes. Consolidation with air bronchogram surrounded by “ground glass” opacities with interlobular septa thickening in the anterior and posterior segment of the right upper lobe.

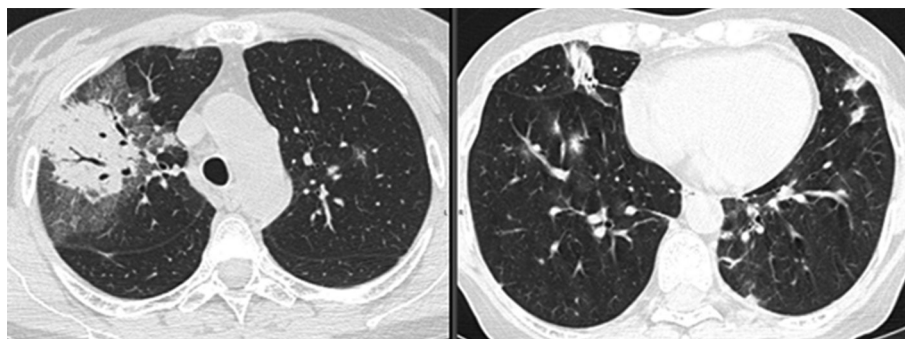


Figure 2. Chest tomography 01/21/2022.

A bronchoalveolar lavage was performed, in case there was an infectious process, with negative results for microorganisms.

Basing on all this information, the patient was diagnosed with noninfectious pneumonitis and began treatment with corticosteroids, 1 mg/kg/d. She showed good therapeutic response, symptom resolution and improved tomographic images after two months of treatment. CT **03/8/2022** (Figure 3): marked size reduction of consolidation in the right corner and disappearance of the other infiltrates in lung parenchyma.

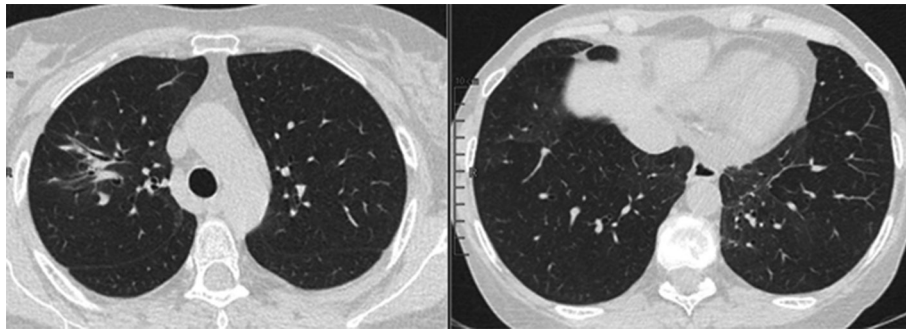


Figure 3. Chest tomography 03/08/2022.

CLINICAL DISCUSSION

Including checkpoint-inhibiting monoclonal antibodies has improved the treatment and prognosis of many patients with cancer.¹ In this type of treatment, several checkpoint routes are used to interfere with anti-tumor immunity, resulting in a higher activation of the patient's immune system.

This treatment is thought to be less toxic than chemotherapy, but may have infectious complications, among other things¹⁻⁵.

The most common adverse effects related to the immune system are cutaneous, and occur in 20% to 50% of patients (rash or pruritus) within the first two cycles. Gastrointestinal effects are manifested from 5 to 10 weeks after the beginning of treatment. Pulmonary effects, such as **noninfectious pneumonitis**, are not so common, they have a 5% incidence rate after 9 to 20 months of treatment; other reviews³ report a median time of 2.6 months. *In our case*, the time to develop pneumonitis was 7 months.

A review published by J. A. Ross et al⁶ describes an **infection rate** of 18% to 19% in patients treated with checkpoint inhibitors, where the use of corticosteroids wasn't associated with a higher risk of infection. The proportion of patients with suspected bacterial infection was 24%, with 8% of confirmed bacterial cultures. 29% of patients who received nivolumab developed an infectious process, and 23% of those who received ipilimumab showed infections. Most patients were treated empirically. No fungal or parasitic infections were identified.

The rates of **noninfectious pneumonitis** were 13% with ipilimumab, compared to 2% with nivolumab. 80% of patients were hospitalized due to noninfectious pneumonitis. According to a published study,³ the most common symptoms are cough (60%) and dyspnea (55%). The most common tomographic patterns are cryptogenic organizing pneumonia (COP), followed in terms of frequency by nonspecific interstitial pneumonia, hypersensitivity pneumonitis, acute interstitial pneumonia/acute respiratory distress syndrome. The most suitable treatment is corticotherapy (85%); 35% of patients began treatment again with nivolumab, and 29% of them showed recurring noninfectious pneumonitis (which improved with corticosteroids). 5% experienced a pneumonia outbreak after completing gradual reduction of corticosteroids.

Most patients received corticosteroids, with a mean time of 6.1 weeks and different doses according to the presentation and evolution of each case.

We presented a patient who developed noninfectious pneumonitis during the course of treatment with immunotherapy, 7 months after the beginning of treatment. Given her clinical spectrum and radiographic patterns, it is important to be sure there's no infectious process. The patient had a good response to the initial treatment with corticosteroids for 2 months, but showed a rebound that responded satisfactorily after administering treatment. This poses the importance of knowing the different scenarios that patients receiving immunotherapy may show, and their difficult management.

Conflict of interests

The authors have no conflict of interests to declare.

REFERENCES

1. Bala-Hampton JE, Bazzell AF, Dains JE. Clinical Management of Pneumonitis in Patients Receiving Anti-PD-1/PD-L1 Therapy. *J Adv Pract Oncol*. 2018;9:422-8. <https://doi.org/10.6004/jadpro.2018.9.4.5>
2. Drakopanagiotakis F, Paschalaki K, Abu-Hijleh M, et al. Cryptogenic and secondary organizing pneumonia: clinical presentation, radiographic findings, treatment response, and prognosis. *Chest*. 2011;139:893-900. <https://doi.org/10.1378/chest.10-0883>
3. Koyama N, Iwase O, Nakashima E, et al. High incidence and early onset of nivolumab-induced pneumonitis: four case reports and literature review. *BMC Pulm Med*. 2018;18:23. <https://doi.org/10.1186/s12890-018-0592-x>
4. Nishino M, Ramaiya NH, Awad MM, et al. PD-1 Inhibitor-Related Pneumonitis in Advanced Cancer Patients: Radiographic Patterns and Clinical Course. *Clin Cancer Res*. 2016;22:6051-60. <https://doi.org/10.1158/1078-0432.CCR-16-1320>
5. Ishiwata T, Ebata T, Iwasawa S, et al. Nivolumab-induced Acute Fibrinous and Organizing Pneumonia (AFOP). *Intern Med*. 2017;56:2311-5. <https://doi.org/10.2169/internalmedicine.8271-16>
6. Ross, JA, Komoda, K, Pal, S, et al. Infectious complications of immune checkpoint inhibitors in solid organ malignancies. *Cancer Med*. 2022;11:21- 7. <https://doi.org/10.1002/cam4.4393>